Brook Niemiec

PERIODONTAL DISEASE STAGING GUIDE

BY DR. BROOK NIEMIEC

Board Certified Veterinary Dentist
American & European Veterinary Dental Colleges





I get asked about staging periodontal disease constantly.

At lectures, in DMs, from new grads, from experienced practitioners who just want a clear framework they can actually use chairside.

So here it is.

This is how I stage. This is how I treat, based on my review of the literature and clinical experience.

Thirty years, 40,000 procedures, and more periodontally compromised mouths than I care to count, distilled into something you can actually use the next time you open a mouth and need to make a decision.

Brook Niemiec

A few things worth knowing before you dive in:

1. 3-mm is normal sulcal depth in dogs. Keep that number in your head, everything flows from it.

2. Pockets deeper than 6-mm cannot be effectively cleaned ***without direct root visualization.*** If you are trying to clean it without a flap you are leaving infection behind, which will only get worse over time.

3. Furcation 1 you can manage closed.
   Furcation 2 and 3 require a flap for cleaning.

4. Bony repair only happens in infrabony pockets and furcation 2. Furcation 3 and horizontal bone loss ***cannot*** be reliably fixed. Know what you are working with before you promise anything.

5. Even if furcation 3 teeth are cleaned with a flap they WILL be infected in weeks. Owners cannot maintain them at home no matter how motivated they are. Factor that into your treatment plan.

6. A solid, non-mobile tooth is not automatically worth saving. If it cannot be cleaned effectively or will become immediately reinfected, the best thing to do is to extract. The most kind thing is often the hard thing.

7. Always evaluate the whole picture prior to creating a treatment plan. Lower incisors will show bone loss and mobility despite normal gingival attachment. Don't let one finding make the decision for you.

8. Periodontal flaps and guided tissue regeneration are effective in the right situation, and referral should be offered. Further, these are techniques which can be learned by GPs with a strong dental interest. Visit vdspets.com to see our upcoming courses.

Okay. Let's stage.

NORMAL — PD 0



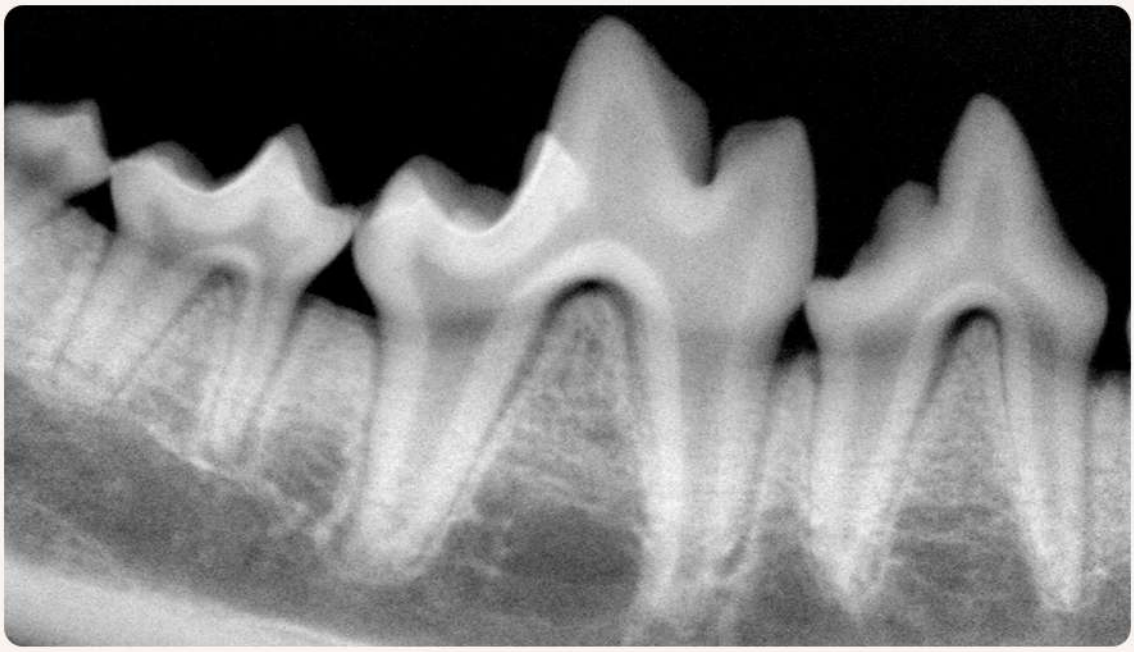

This is what we are working toward. No inflammation. No bleeding on probing. Normal alveolar margin.
Pockets under 3-mm.

No mobility. Nothing to treat, just everything to protect.

What to do?

Professional cleaning under general anesthesia once a year. Daily brushing at home. Tell the owner this is what good looks like and help them keep it this way.

This is the easiest conversation you will have all day. Enjoy it.

STAGE 1 — PD 1

Gingivitis



The gums are red and/or swollen.There is bleeding on probing. No attachment loss yet, the bone is still intact, the architecture is normal, pockets are under 3-mm.

Here is what most people miss at this stage: the bleeding comes before the redness. Before the swelling. Before the bad breath. Bleeding on probing is the first sign and it is the one sign that most owners, and a lot of vets, walk right past.

Bacteria are already below the gumline and already entering the bloodstream. This is the beginning of both local and systemic infection.

There are systemic consequences of periodontal disease which start with just gingivitis — however the burden increases with the severity of the disease. Chronic oral bacteremia has real consequences for the heart, kidneys and liver. The infection does not stay in the mouth.

What to do?

Professional cleaning under general anesthesia. Real home care, not a suggestion, a protocol. This is the only stage we can fully reverse and most pets never get caught here. When you find it, make it count.

STAGE 2– PD 2

Early Periodontitis



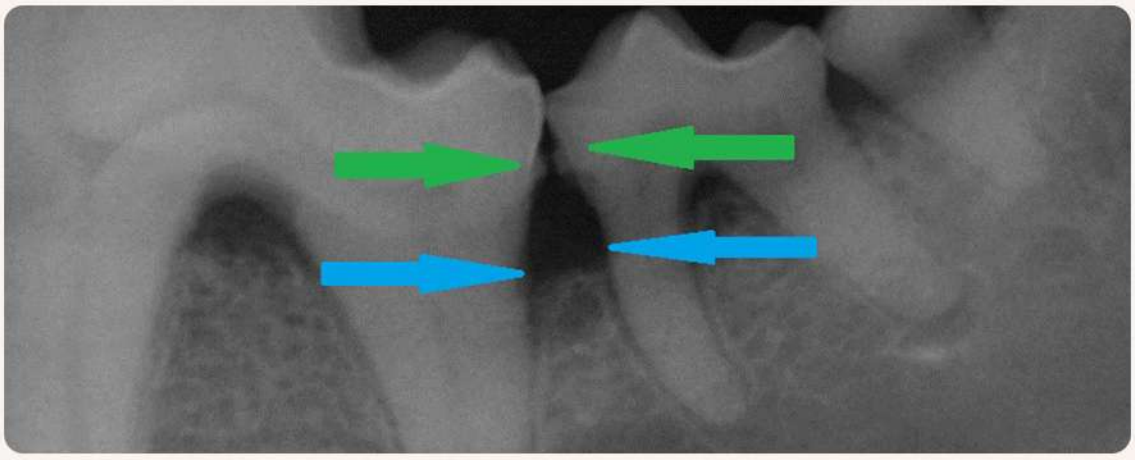

Less than 25% attachment loss. Furcation 1 at most. Pockets between 3 and 6-mm. No mobility.

The infection has gone below the gumline and taken some bone with it. That bone is not coming back without advanced regenerative techniques, but we can absolutely stop this from getting worse. The pet is probably not showing obvious signs. They are eating. They seem fine. **They are not fine.**

Where to start?

Professional cleaning under general anesthesia with closed root planing. Perioceutic therapy as indicated. This stage responds well to treatment, but only if the home care is real and consistent. Have that conversation with the owner before you start.

STAGE 3 — PD 3

Moderate Periodontitis





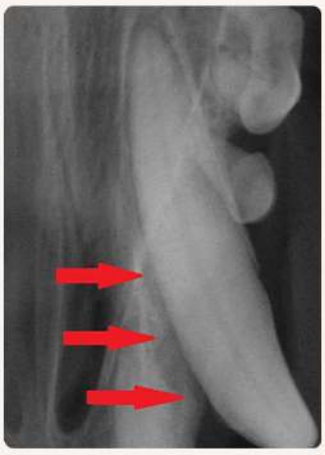

25 to 50% attachment loss.

Furcation 2.

Pockets deeper than 6-mm.

Grade 1 mobility.

This is where the decision gets harder. Pockets over 6-mm cannot be effectively cleaned without direct visualization, if you are scaling blind in a 7-8-9mm pocket, you are not proper doing dentistry. You are going through the motions.

Furcation 2 means the bacterial induced inflammation has destroyed the bone between the roots.
All of these conditions require a periodontal flap. Guided tissue regeneration is on the table for infrabony defects and furcation 2, but be honest with yourself about what the radiograph is actually showing before you promise regeneration.

What to do?

Periodontal flap surgery +\- guided tissue regeneration, or extraction. This is not a closed treatment situation — after just a prophy or closed scaling is not enough. If you cannot do the flap, ***refer or extract.***

Leaving a stage 3 tooth with a closed prophy is not a treatment plan.

STAGE 4 – PD 4

Advanced Periodontitis







More than 50% attachment loss.

Mobility grade 2 or 3.

Furcation 3.

I want to be clear about something: teeth at stage 4 are not automatically a lost cause and they are not necessarily loose.

But furcation 3 is a different animal. You can clean it (with an effort — flap and meticulous cleaning), but it will be reinfected within weeks because no owner on earth can maintain it at home. That is not a reflection on the owner.

It is just the anatomy. Some deep infrabony pockets can be treated with a flap and guided tissue regeneration, especially large and strategic teeth.

What to do?

Extraction is the standard recommendation. In very rare cases a periodontal flap may still be considered — but the prognosis is guarded and the clinical picture must be evaluated carefully and completely. Referral is strongly recommended.

The last thing I want to say

Every stage 4 mouth I have ever treated started as a stage 1.

That is not said to make anyone feel guilty. It is said because it means every stage 4 mouth was preventable. Annual exams. Full mouth radiographs. Home care that actually happens.

If you take one thing from this guide, make it this. The mouth you assess today is not static. It is either getting better or getting worse. What you do with that information is the difference.

Thanks for reading.

Now go look in some mouths.

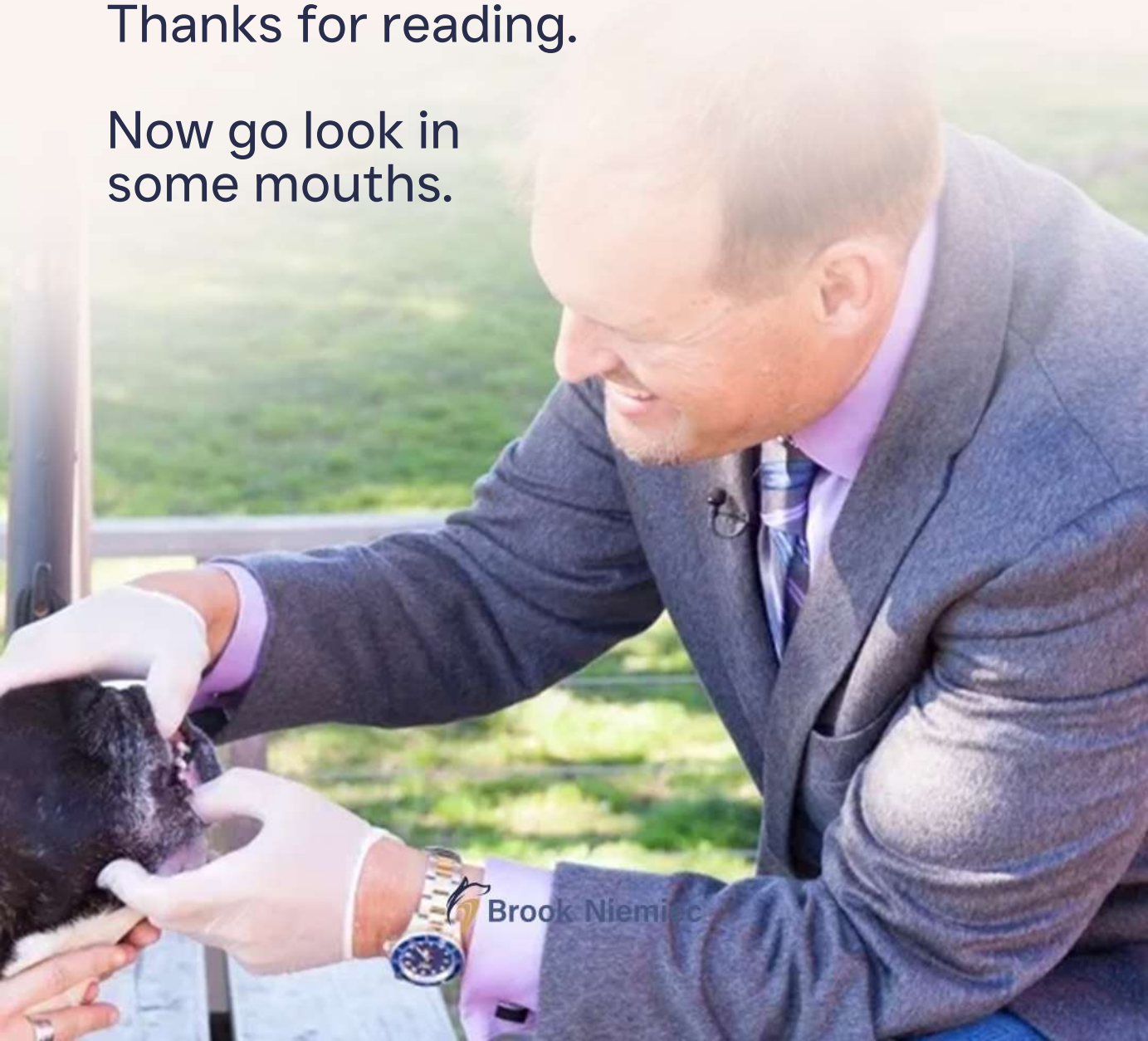



Board Certified Veterinary Dentist — American & European Veterinary Dental Colleges. One of fewer than 10 veterinarians in the world to hold both certifications. Fellow of the Academy of Veterinary Dentistry. Chair of the WSAVA Dental Guidelines Committee. 40,000 procedures. 16 clinics. Still learning.

@dr_brook_niemiec

drbrookniemiec.com

Brook Niemiec